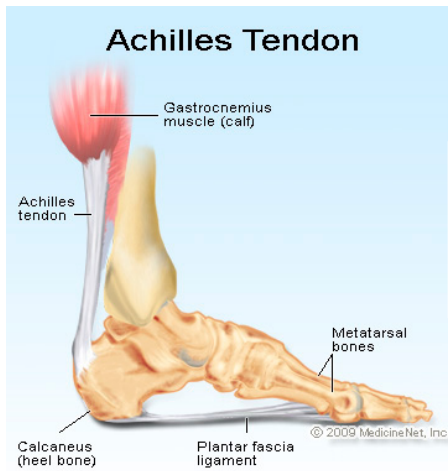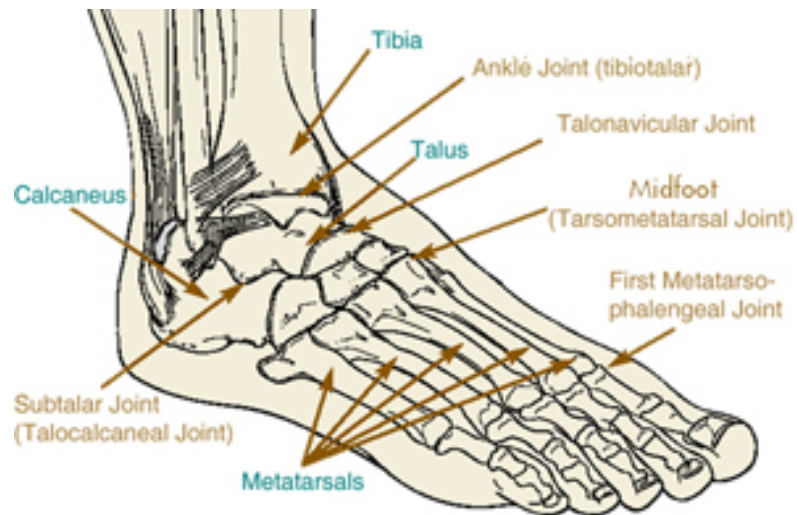
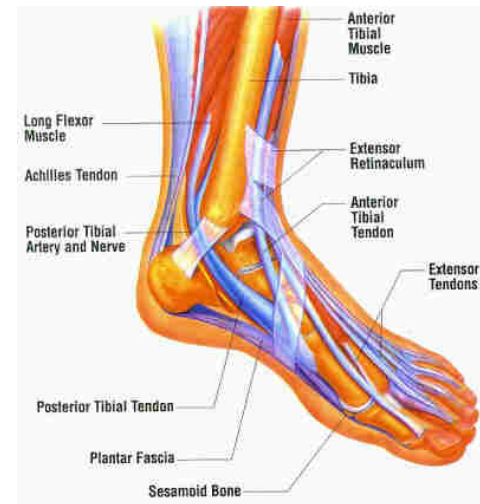


## Heel Spur



## Tibiotalar Joint

### 1<sup>st</sup> IP Joint Space

## Morton's Neuroma

